420 CSVP Contributor's Diagnosis

Date: Nov 20, 2026

Time: 12 : 00~16 : 00

Place: NCHU

專題演講(12:00~13:00)：病理獸醫師在藍耳病防控的現場操作-成功案例分享(游能凱 獸醫師)

本次會議組織病理切片資訊：https://ivpems.nchu.edu.tw/slidecenter.php?id=586

Case 1. CSVP 2026-3332 (NTU2026-0762, GIMCP, C.S. Tseng, H.W. Chang, Y.C. Chang, C.H. Shih, C.F. Kao, C.Y. Tsai, and W.H. Huang)

Feline, Maine Coon, female spayed, 1-year-old. Bilateral hindlimb lameness was noted several weeks before femoral head and neck excision. Radiographs revealed bilateral femoral head physeal fractures, suggestive of slipped capital femoral epiphysis (SCFE).

Morphological diagnosis:

Mass: Physeal fracture, with physeal dysplasia, osteolysis, and granulation tissue and woven bone formation, bilateral femoral head and neck

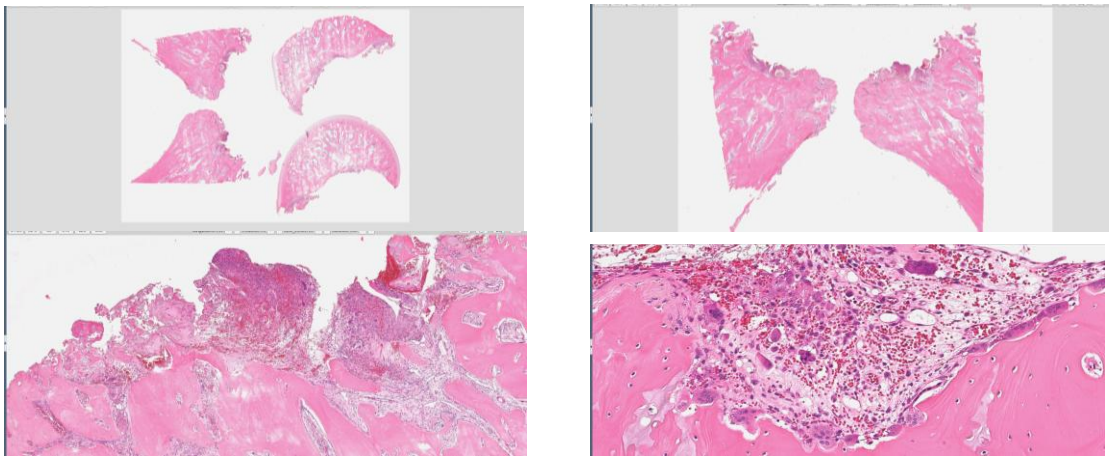

Dx. : Slipped Capital Femoral Epiphysis (SCFE) in a Maine Coon

Case 2. CSVP 2026-3333 (MN26019, ADDC NCYU, C.H. Chang, Y.P. Lo, C.C. Cheng, H.C. Kuo, and D.Y. Lo)
Broiler breeder, 25-week-old, showed depression, inappetence, recumbency, and paralysis. The mortality rate was 1%. At necropsy, ascites, hepatomegaly, and splenomegaly were observed

Morphological diagnosis:
1. Myelocytoma, Sternal mass.
2. Myelocytomatosis, multifocal, severe, chronic, liver, spleen, lung, kidney, trachea and ovary.

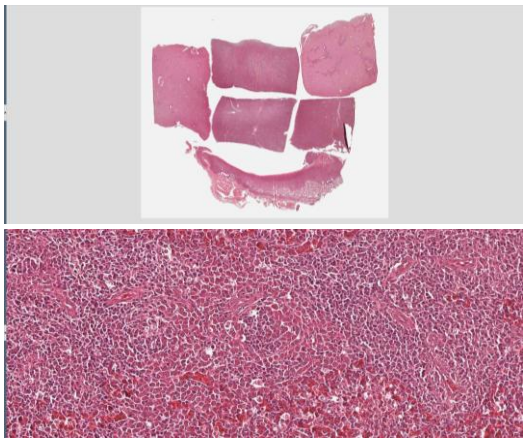

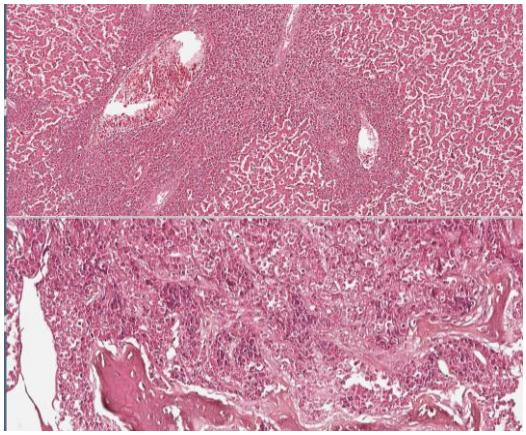

Lab. examination :
IHC: Target marker: gp85 (env of ALV-J) Liver, kidney, heart, lung, sternal mass (+)
Bacterium culture: Blood agar, MaConkey agar for *Salmonella* spp (-)

PCR & RT-PCR:
Liver, Spleen: MDV (-)
Liver, Spleen: AVL-A (-), AVL-K (-), AVL-L (+), ALV-J clade 1（HPRS-103 like）Taiwan 2021–2023
Liver, Spleen: REV (-)

Dx: Avian leukosis in broiler breeder chickens

Case 3. CSVP 2026-3334 (OT114-122-3, OT115-246-2, ADDC NPUST, Y.H. Hsieh, S.C. Huang, and Y.C. Li)

Canine, mixed-breed, 2.5-year-old, male. A mass on the left eyelid recurred one month after surgical excision. Subsequently, a cutaneous mass developed on the dorsal aspect of the head, accompanied by thickening of the left lip and progressively worsening respiratory noise. Computed tomography (CT) revealed masses in the nasal cavity and choanae, with associated nasal turbinate destruction.

Morphological diagnosis:

Skin at head: Hamartoma, with mild myodegeneration

Mass at the left eyelid: Lipoma, with foreign body-induced inflammation, hemorrhage, edema and fibrosis

Biopsies of the left upper lip: Suspected infiltrative lipoma, with mild myodegeneration

Biopsies of nasal cavity: Rhinitis, lymphoplasmacytic, mild, chronic, with marked fibroplasia and mild edema

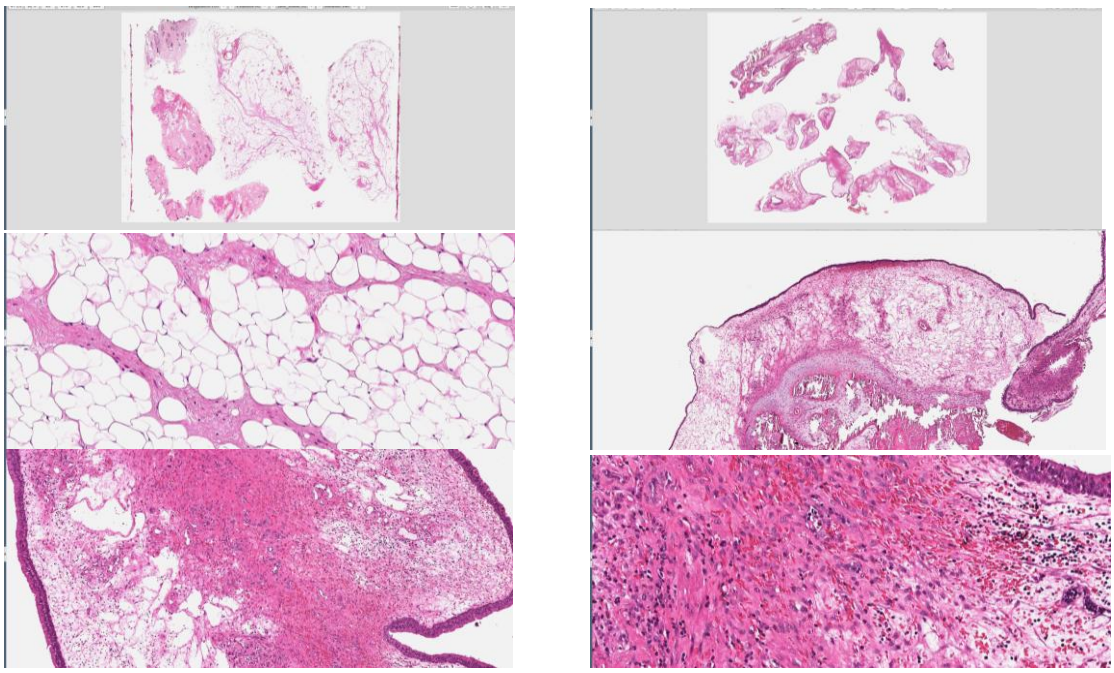

Dx: Nasal fibromatosis in a dog

切片名稱：**Case 4. BC2026051401**

Case 4. CSVP 2026-3335 (BC2026051401, BioLASCO PTRC, C.L. Ho, K.C. Yen and W.J. Hsieh)

Feline, domestic mixed-breed, female spayed, 5-year-2-month-old. The cat developed sudden swelling of all four paws, followed by a 1-cm mass on the left forepaw with recurrent ulceration and bleeding. The paw swelling subsided following treatment with doxycycline and prednisolone, but the mass persisted and was subsequently excised for histopathologic examination.

Morphological diagnosis:

Pad: Pododermatitis plasmacytic, ulcerative and pyogranulomatous, severe, chronic, focal, left forepaw pad.

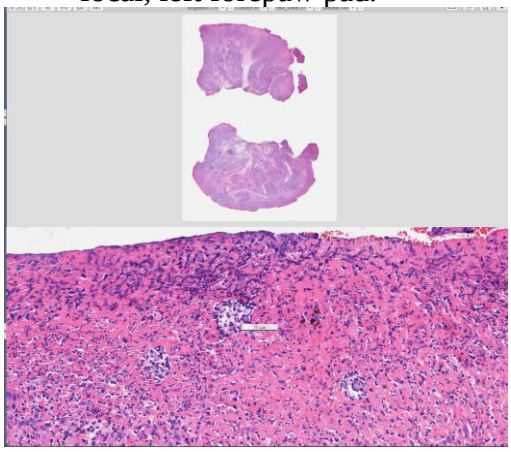

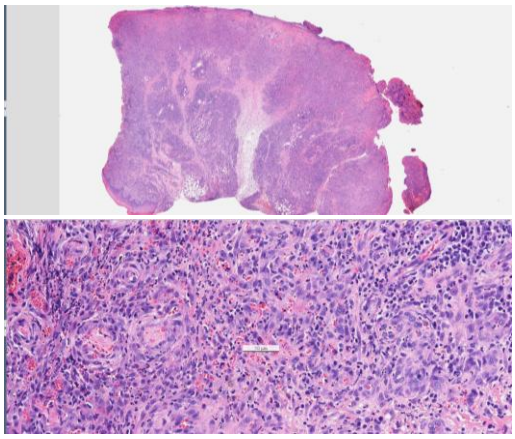

Lab. examination :

Toluidine Blue (-); PAS (-),

IHC: MUM1 (for B-cell lymphoma and melanocytic lesions): (-); CD79a (for plasma cell) (+)

Congo Red Under Polarized Light (-)

Dx: Feline plasma cell pododermatitis

切片名稱：**Case 5. 11586**

Case 5. CSVP 2026-3336 (#115-86, NIAR NCB, TY Chen and KH Lee)

Guinea pig, 13-month-old, female. No apparent clinical abnormalities were observed prior to euthanasia. Hepatic lesions were noted at necropsy

Morphological diagnosis:

Liver: Coagulative necrosis, multifocal to coalescing, random, moderate, with mild inflammatory cell infiltration, bile duct proliferation and minimal dystrophic mineralization and fibrosis.

Kidney: Regeneration, tubular, cortex, minimal.
Mineralization, tubular, medullary, minimal

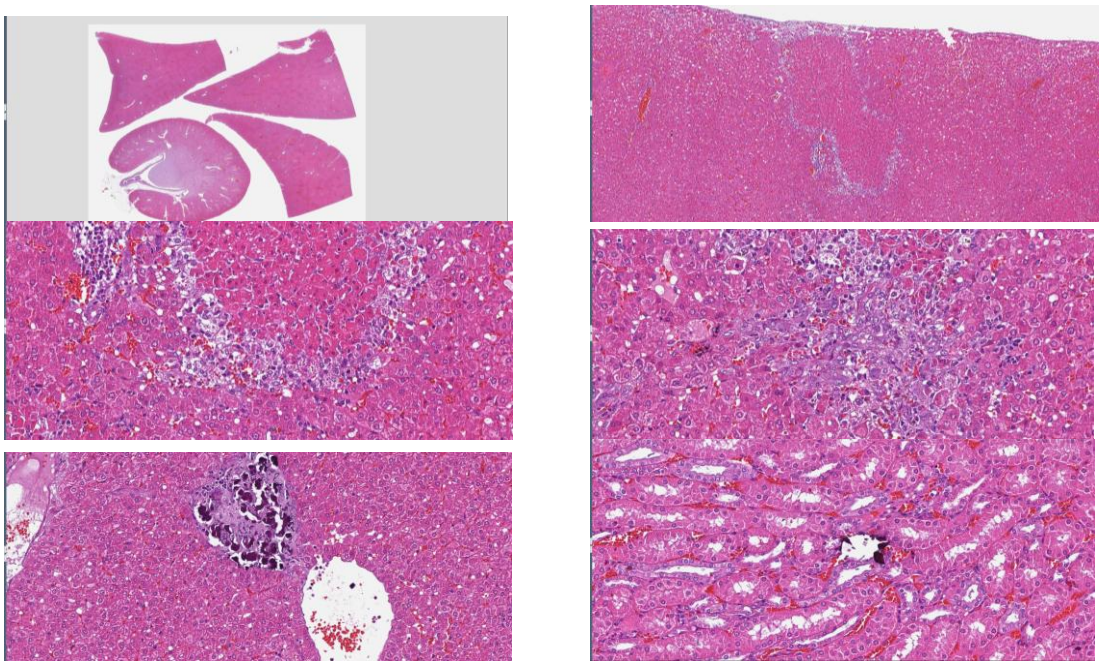

Dx.: Spontaneous Multifocal Hepatic Necrosis in Guinea Pig

切片名稱：**Case 6. CM2607004C**

Case 6. CSVP 2026-3337 (CM26-07004, ADDC NCHU, Y.S. Lin, Y.C. Chen, F.H. Hou, Y.H. Lee, and H.Y. Chiou)

Suckling pigs, 2-week-old, showed extensive, dark brown exudative crusts over red, inflamed skin. The condition affected 7 out of 20 litters

Morphological diagnosis:

1. Haired skin:

Epidermitis, exudative, proliferative and pustular, multifocal to coalescing, moderate, with dermal abscess, ulceration and mild superficial dermatitis and intracorneal cocci

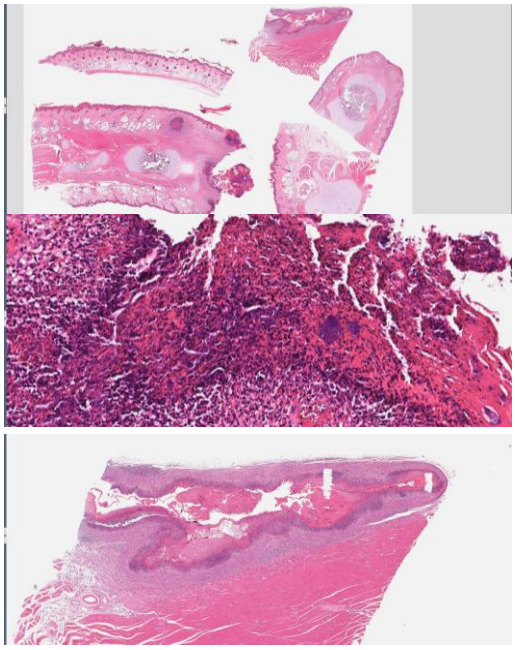

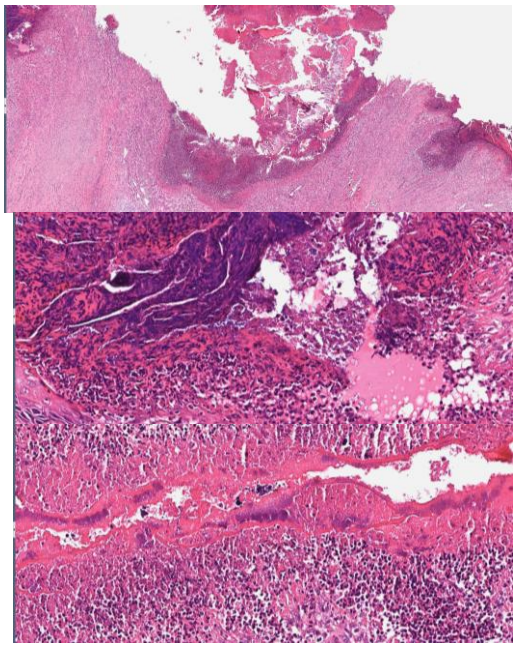

Lab. examination :

Microbiological examinations:
Skin: (3+) *Staphylococcus hyicus* (+)
Synovial fluid (2+) *Staphylococcus hyicus* (+)
Ileum: (4+) *Clostridium perfringens*; (4+) *Escherichia coli*

PCR:
Serum: PRRSV2 — Negative; PCV2 — Negative
Tissue PRV — Negative
Skin: *Staphylococcus hyicus* 16S rRNA (27-1492) BLAST percent identity: 99%
Small intestine content: *Clostridium perfringens* (+) 16S rRNA (27-1492) BLAST percent identity: 99%; *Escherichia coli* GNB14 Highly supportive *E.coli*

Dx: Exudative Epidermitis in Suckling Pigs